

## Background

Rasmussen's encephalitis is a rare neurological disease, describe as a chronic, progressive encephalitis developed in childhood and characterized by intractable focal seizures and progressive multifocal neurological symptoms such as hemiparesis and cognitive impairment. Tends to be localized usually in one hemisphere, some cases had been described with bilateral affection. Recent reports of this entity highlighted the importance of functional imaging in their study.

## Objetives

The aim of this paper is to describe the cases with Rasmussen's encephalitis and demonstrate the role of PET / CT with <sup>18</sup>F-FDG.

## Methods

Within 1360 <sup>18</sup>F-FDG PET/CT scan performed between June 2012 to February 2015, 4% were for evaluation of neurological disease. Of this, 44 patients present refractory epilepsy (85%) including two adolescent patients with previous functional hemispherectomy and histological diagnosis of Rasmussen's encephalitis. Due to seizure recurrence, a brain <sup>18</sup>F-FDG PET/CT scan was requested to determine extent of disease prior to new surgery. MRI of both cases only showed cortical atrophy in the remaining cerebral cortex post-hemispherectomy, without other significant changes. The PET/CT studies were performed in a hybrid computer - BIOGRAPH mCT128 SIEMENS (Siemens, Germany) previous intravenous administration of 1 <sup>18</sup>F-FDG, with qualitative and semiquantitative evaluation.

## Afiliations

1,2, Nuclear Medicine Unit of Fundación Valle del Lili, Cali, Colombia

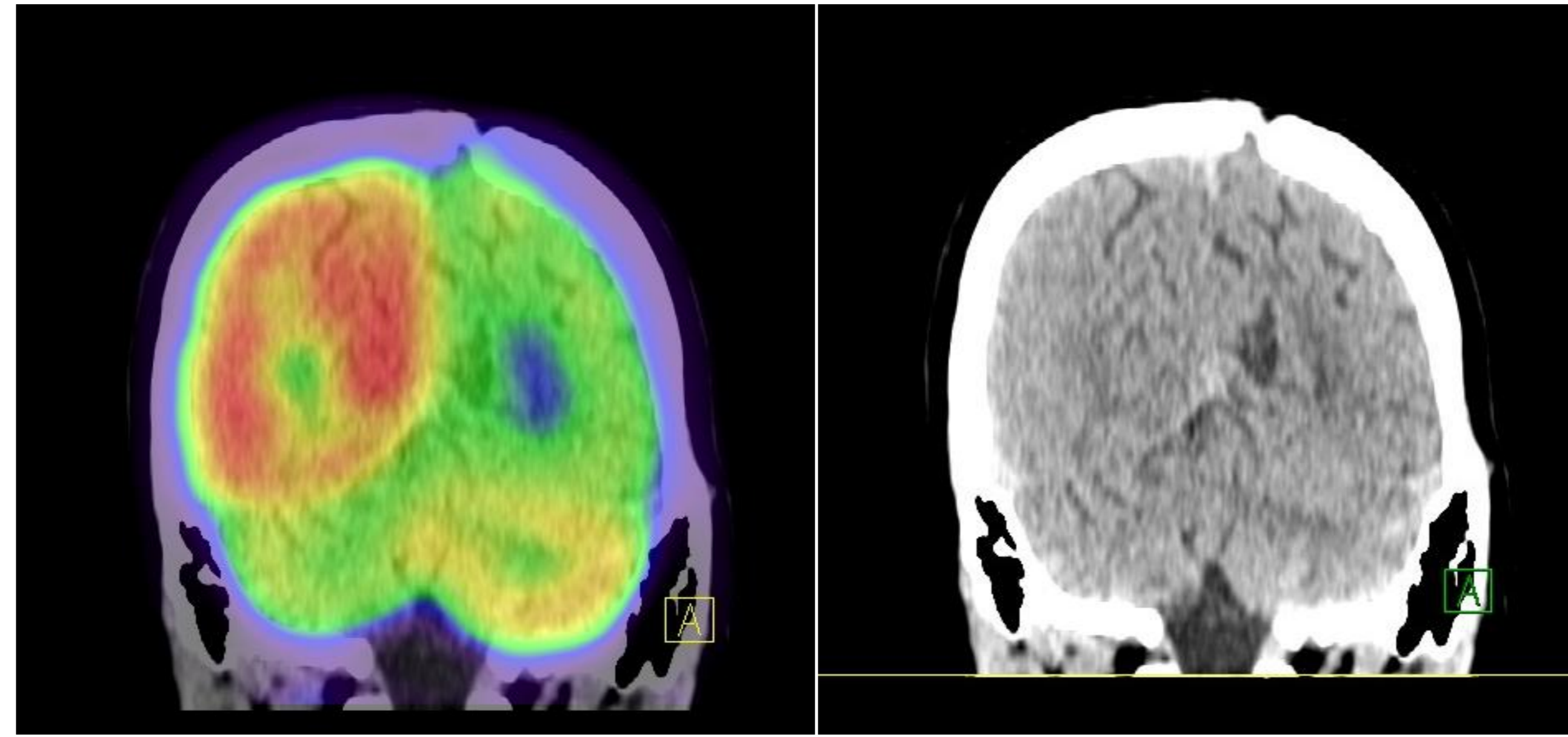
3-6Diagnostic Imaging of Fundación Valle del Lili, Cali, Colombia

7Clinical Research Center of Fundacion Valle de Lili, Cali. Colombia

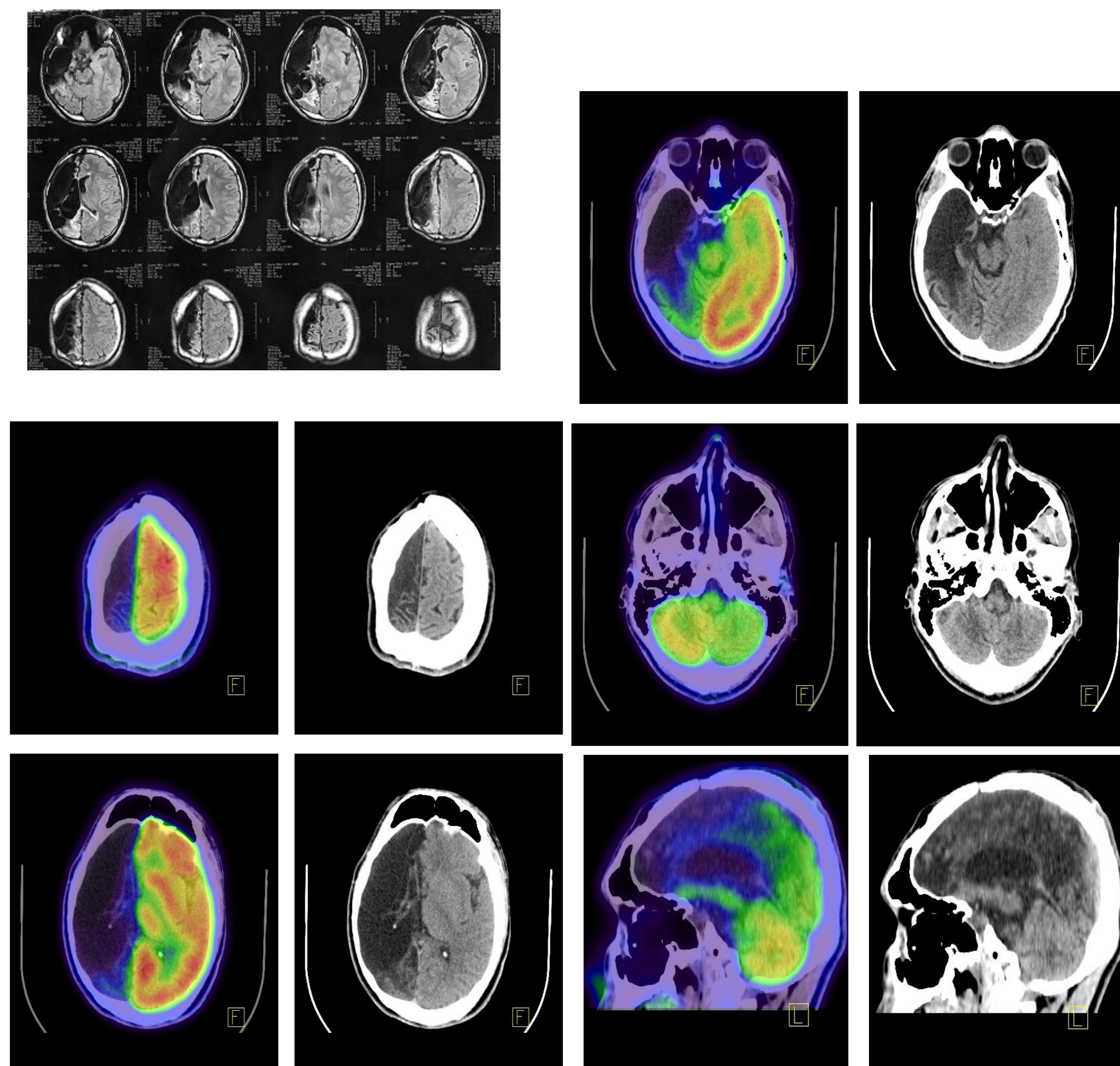
## Results

In both cases, the PET scan showed moderate to severe hypometabolism in the remaining cerebral cortex post-hemispherectomy and crossed cerebellar diaschisis, suggesting to be the epileptic focus.

### CASE 1. PET/CT scan



### CASE 2. MRI and PET/CT scan



## Conclusion

Brain <sup>18</sup>F-FDG PET/CT scan is useful for the evaluation of Rasmussen's encephalitis. Although cerebral MRI is an excellent tool for seizure disorders evaluation, correlation with PET/CT with FDG increases the pre-surgical diagnostic confidence allowing the exact identification cortical area functional affected.

## Bibliography

1. Bien CG, Granata T, Antozzi C, et al. Pathogenesis, diagnosis and treatment of Rasmussen encephalitis: a European consensus statement. *Brain*. 2005.454-71.
2. Carrillo Herranz A, Sánchez Pérez I, Aparicio Meix JM, et al. Rasmussen's syndrome, an autoimmune disease. *An Pediatr* 2003.187-9.
3. Fiorella DJ, Provenzale JM, Coleman RE, et al. 18F-fluorodeoxyglucose positron emission tomography and MR imaging findings in Rasmussen encephalitis. *AJNR Am J Neuroradiol*. 2001.1291-9.
4. Fogarasi A, Hegyi M, Neuwirth M, et al. Comparative evaluation of concomitant structural and functional neuroimages in Rasmussen's encephalitis. *J Neuroimaging*. 2003.. 339-45.
5. Maeda Y, Oguni H, Saitou Y, et al. Rasmussen syndrome: multifocal spread of inflammation suggested from MRI and PET findings. *Epilepsia*. 2003.1118-21.
6. Ochoa-Figueroa M, Cárdenas-Negro C, Allende-Riera A, et al. Papel de la 18 F-FDG PET en el diagnóstico de la Enfermedad de Rasmussen. *Revista Española de Medicina Nuclear e Imagen Molecular*. 2012. 286-7.
7. Owolabi M. *Rasmussen's Encephalitis: An Overview*. INTECH Open Access Publisher, 2011.